



THE UNIVERSITY *of* EDINBURGH

Edinburgh Research Explorer

## Mathematically Reliable Stereological Measurement of Motion Corrected Fetal Brain Volume

**Citation for published version:**

Anblagan, D, Yin, K, Reynolds, R, Denison, F, Bastin, M, Studholme, C, Norman, J, Semple, S & Roberts, N 2013, 'Mathematically Reliable Stereological Measurement of Motion Corrected Fetal Brain Volume', Organization for Human Brain Mapping, Seattle, United States, 16/06/13 - 20/06/13.

**Link:**

[Link to publication record in Edinburgh Research Explorer](#)

**Document Version:**

Peer reviewed version

**General rights**

Copyright for the publications made accessible via the Edinburgh Research Explorer is retained by the author(s) and / or other copyright owners and it is a condition of accessing these publications that users recognise and abide by the legal requirements associated with these rights.

**Take down policy**

The University of Edinburgh has made every reasonable effort to ensure that Edinburgh Research Explorer content complies with UK legislation. If you believe that the public display of this file breaches copyright please contact [openaccess@ed.ac.uk](mailto:openaccess@ed.ac.uk) providing details, and we will remove access to the work immediately and investigate your claim.



# Mathematically Reliable Stereological Measurement of Motion Corrected Fetal Brain Volume

---

**Abstract Submission No:**

1500

**Authors:**

Devasuda Anblagan<sup>1</sup>, Kaiming Yin<sup>1</sup>, Rebecca Reynolds<sup>1</sup>, Fiona Denison<sup>1</sup>, Mark Bastin<sup>1</sup>, Colin Studholme<sup>2</sup>, Jane Norman<sup>1</sup>, Scott Semple<sup>1</sup>, Neil Roberts<sup>1</sup>

**Institutions:**

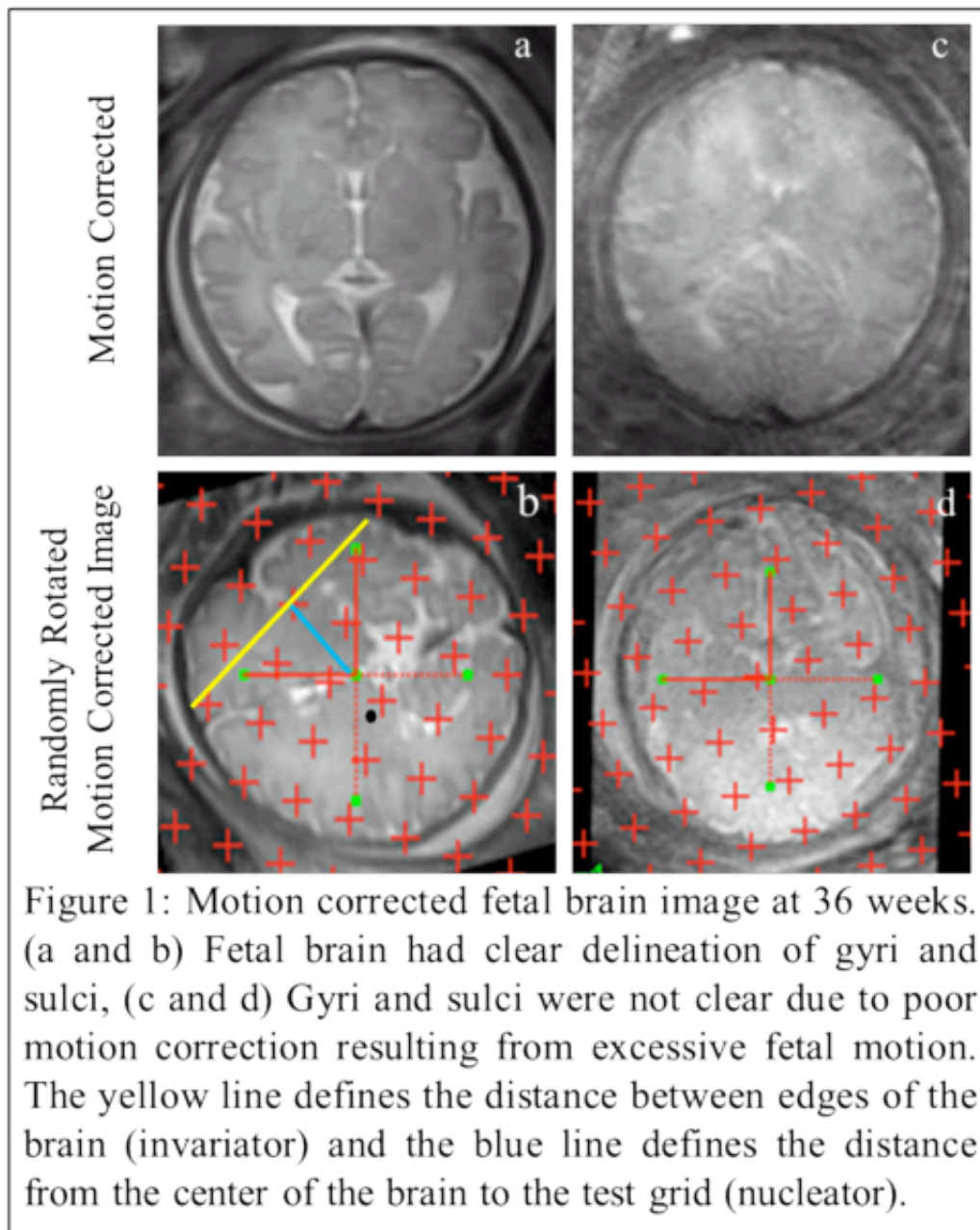
<sup>1</sup>University of Edinburgh, Edinburgh, United Kingdom, <sup>2</sup>University of Washington, Seattle, WA, United States

**Introduction:**

Motion correction is now possible for fetal brain (FB) MRI studies in both the 2nd and 3rd trimester, however techniques to segment these images are still under development. We describe the first application and practicality, time efficiency and precision of Isotropic Cavalieri (IsoC), Invariator (InV) and Discretized Nucleator (DNuc) stereology methods for estimating fetal brain volume (FBV) on motion corrected 3D images.

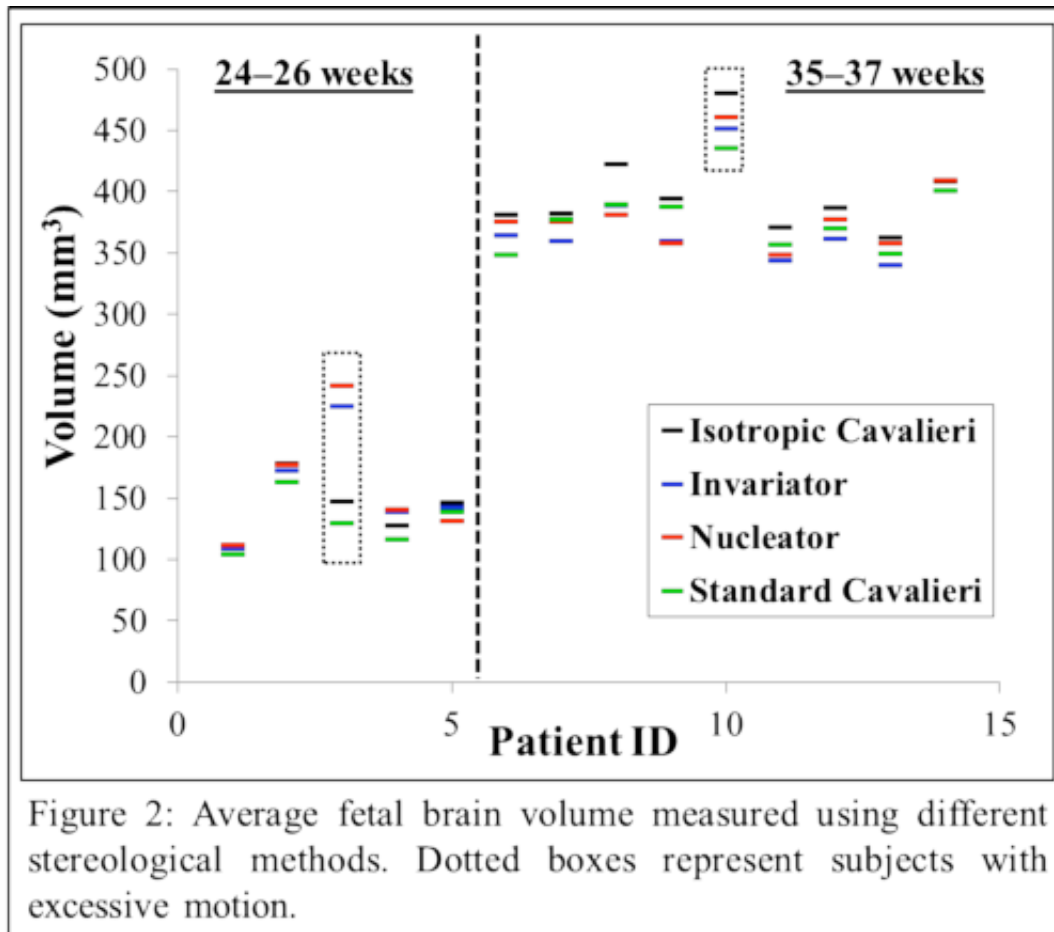
**Methods:**

15 pregnant women were recruited and gave informed consent to be imaged on a MAGNETOM Verio 3T system (Siemens AG, Germany): 9 at 24–26 weeks and 6 at 35–37 weeks gestation. HASTE acquisitions of the fetal brain were obtained (25–45 slices, TE = 94 ms and TR = 4200 ms, SAR < 2.0 W kg<sup>-1</sup>, 0.55 × 0.55 × 3 mm<sup>3</sup> voxels) three times in each of axial, sagittal and coronal scanning directions. The image series were motion corrected using Slimmer tool<sup>1</sup> to form a single 3D high-resolution brain image (1 × 1 × 1 mm<sup>3</sup> voxels) and used to estimate FBV using stereological methods<sup>2</sup> (IsoC, InV and DNuc) using Analyze 10.0 software (MAYO Foundation, USA). Beginning from a random starting position, the IsoC method involves sampling the brain with a series of images a constant distance  $T$  apart along a random orientation in 3D. Sections were analyzed using point counting. The InV method alternatively requires only a single isotropic section to be obtained through a fixed point in the 3D image volume. Orthogonal chord lengths within the brain are then measured using a T-shaped measurement tool as shown in Fig. 1b (yellow line). The DNuc method is similar to InV, except that now the length of the radial arm of the T-shaped measurement tool is directly measured from the fixed point to each test point lying within the brain (Fig. 1b, blue line). All three methods were applied in three random mutually orthogonal orientations. The Cavalieri method was also applied directly to the original axial, sagittal, and coronal HASTE datasets.



### Results:

Reconstruction of the fetal brain was possible in all cases except for a dataset acquired at 25 weeks due to excessive fetal motion. Efficiency measures (time, precision) was lowest for the InV (10–15 minutes, 2–37%), followed by IsoC and DNuc (both 5–10 minutes, 0–5% and 4–37% respectively). As expected, there was excellent agreement between the FBV estimates obtained from each of the orthogonal IsoC series, and much greater variation between the FBV estimates obtained from the 3-orthogonal InV or DNuc sections but with the mean always close to the results obtained using the IsoC method. Estimates obtained by applying the Cavalieri method to the uncorrected datasets were variable depending on the scale of motion (Fig. 2). The quality of fetal head motion correction using SLIMMER depends greatly on the degree of fetal motion; this was generally greater during the 2nd trimester and more challenging to correct for than in the 3rd trimester when the fetal head is frequently engaged in the maternal pelvis. Furthermore, even when the motion correction algorithm has been successfully applied, the gyri and sulci of the fetal brain may still not be clearly depicted on the reconstructed 3D image. This affects the ease of performing surface area measurement (Fig. 1d), which as well as being interesting in its own right, is a prerequisite for application of the mathematical formula developed by Cruz-Orive<sup>2</sup> for predicting the precision of volume estimates obtained using the IsoC method. Accordingly, surface area measurements were only possible on 3 datasets from 2nd and 6 from 3rd trimester.



### Conclusions:

We have demonstrated high levels of agreement between FBV measurements obtained by applying three new stereological methods to motion corrected 3D MR images of the fetal brain. IsoC is the most precise method and is recommended for detailed studies in individual subjects while InV and DNuc could be used in measuring the change in mean brain volume in a cohort of subjects.

### Modeling and Analysis Methods:

Other Methods

[1] Kim, K. (2010), 'Intersection Based Motion Correction of Multi-Slice MRI for 3D in utero Fetal Brain Image Formation', IEEE Trans. Med. Imaging, vol. 29, no. 1, pp. 146-158. [2] L.M.Cruz-Orive (2010), 'Stereology of isolated objects with the invariator', Journal of Microscopy, vol. 240, no. 2, pp. 94-110.