



THE UNIVERSITY *of* EDINBURGH

Edinburgh Research Explorer

Quantitative myocardial inflammation assessed using a novel USPIO-Magnetic Resonance Imaging acquisition and analysis protocol

Citation for published version:

Semple, S, Alam, SR, Macgillivray, TJ, Dweck, MR, Shah, AS, Richards, J, Wang, C, Lang, N, Mckillop, G, Mirsadraee, S, Pessotto, R, Zamvar, V, Henriksen, P & Newby, D 2013, 'Quantitative myocardial inflammation assessed using a novel USPIO-Magnetic Resonance Imaging acquisition and analysis protocol', *Journal of Cardiovascular Magnetic Resonance*, vol. 15, no. Suppl 1, pp. O114.
<https://doi.org/10.1186/1532-429X-15-S1-O114>

Digital Object Identifier (DOI):

[10.1186/1532-429X-15-S1-O114](https://doi.org/10.1186/1532-429X-15-S1-O114)

Link:

[Link to publication record in Edinburgh Research Explorer](#)

Document Version:

Publisher's PDF, also known as Version of record

Published In:

Journal of Cardiovascular Magnetic Resonance

Publisher Rights Statement:

Available under Open Access.
© 2013 Semple et al; licensee BioMed Central Ltd.

General rights

Copyright for the publications made accessible via the Edinburgh Research Explorer is retained by the author(s) and / or other copyright owners and it is a condition of accessing these publications that users recognise and abide by the legal requirements associated with these rights.

Take down policy

The University of Edinburgh has made every reasonable effort to ensure that Edinburgh Research Explorer content complies with UK legislation. If you believe that the public display of this file breaches copyright please contact openaccess@ed.ac.uk providing details, and we will remove access to the work immediately and investigate your claim.



ORAL PRESENTATION

Open Access

Quantitative myocardial inflammation assessed using a novel USPIO-Magnetic Resonance Imaging acquisition and analysis protocol

Scott Semple^{1,2*}, Shirjel R Alam¹, Tom J MacGillivray^{1,2}, Marc R Dweck^{1,3}, Anoop S Shah¹, Jenny Richards^{1,4}, Chengjia Wang^{1,2}, Ninian Lang^{1,3}, Graham McKillop⁵, Saeed Mirsadraee^{2,5}, Renzo Pessotto⁶, Vipin Zamvar⁶, Peter Henriksen^{1,3}, David Newby^{1,3}

From 16th Annual SCMR Scientific Sessions
San Francisco, CA, USA. 31 January - 3 February 2013

Background

Ultrasmall superparamagnetic particles of iron-oxide (USPIO) particles can be used as a magnetic resonance imaging contrast (MRI) agent. Due to their dextran coating and small diameter (<30 nm), they are phagocytised by inflammatory cells [1].

The aim of this study was to assess whether a novel acquisition/registration USPIO-MRI protocol could be used to assess myocardial cellular inflammation. Myocardial infarction and cardiac surgery was used to model myocardial inflammation [2]. An influx of macrophages can be seen in post-mortem histology, however the dynamics of in vivo patho-physiology is uncertain [3].

Methods

16 patients underwent MRI 2-4 days after ST-elevation myocardial infarction (STEMI) at baseline and 24-hours after intravenous USPIO infusion (4 mg/kg; Ferumoxytol, AMAG; n=10) or no infusion (n=6). Between 5 and 28-days following on-pump coronary artery bypass graft (CABG) surgery, 32 patients underwent the same protocol with all patients receiving USPIO.

3T-MRI (Siemens Medical) was performed to optimise USPIO sensitivity. Baseline and 24-hour multi-echo T2*-weighted sequences were spatially registered to generate an R2* (1/T2*) map to assess USPIO uptake. R2* maps were spatially registered using custom software (Matlab/Analyze) to late gadolinium enhancement (LGE) images to confirm USPIO localisation in the infarct zone. CABG R2* maps were analysed using a standard 17-segment model.

Data comparing CABG to MI cohorts was analysed by one-way and repeated measures ANOVA with Dunn's post-test. Data comparing change in R2* values within cohorts was analysed by Wilcoxon matched pairs test.

Results

Consistent with reticuloendothelial uptake, R2* values increased in the liver & spleen following USPIO administration. In the myocardial infarct, there was a large R2* increase from 41.0±12.0 (baseline) to 155±45.0 s⁻¹ (p<0.001) at 24h. A lower magnitude response was seen in the remote myocardium from 39±3.2 to 80±14.9 s⁻¹ (p<0.002), consistent with myocardial inflammation that occurs post infarction [4].

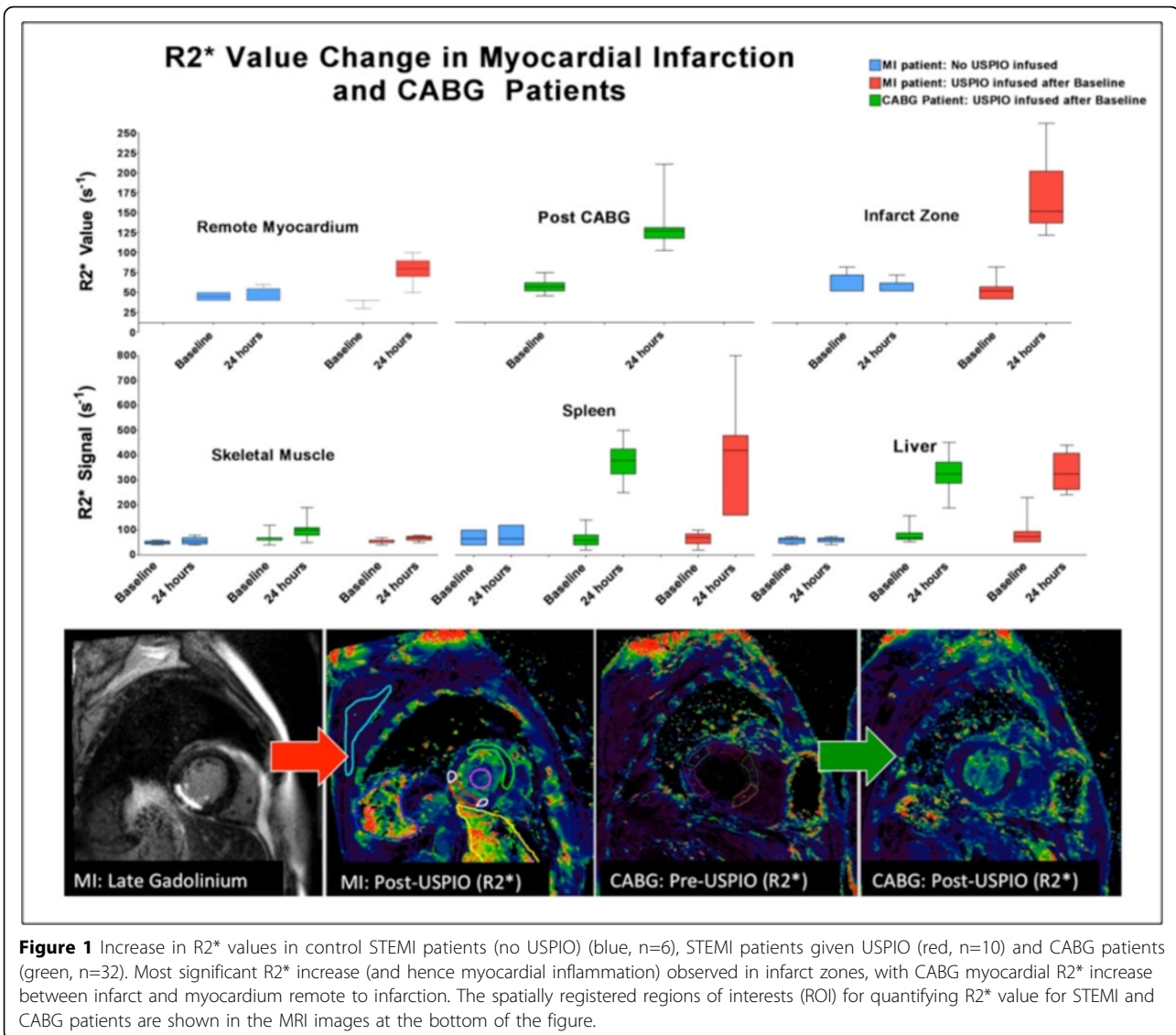
In CABG patients the R2* signal increased: 45±7s⁻¹ to 118± 22 s⁻¹ at 24h (p<0001). The increase in myocardial R2* values was greater than in the remote myocardium of patients with STEMI, but lower than the infarct zone itself (p<0.001 and p<0.05 respectively).

Conclusions

USPIO are taken up into inflamed myocardial tissue and can be quantitatively assessed using a multi-parameter MRI acquisition protocol with optimised spatial registration analysis based on a custom mutual information algorithm.

This represents a novel imaging technique of assessing myocardial inflammation, as well as providing a useful research tool in investigating tissue inflammation.

¹Centre for Cardiovascular Research, University of Edinburgh, Edinburgh, UK
Full list of author information is available at the end of the article



Funding

Funding was provided by the Medical Research Council, Chest Heart & Stroke Scotland, the British Heart Foundation and the Scottish Universities Physics Alliance.

The Welcome Trust Clinical Research Facility and the Clinical Research Imaging Centre are supported by NHS Research Scotland (NRS) through NHS Lothian.

Author details

- Centre for Cardiovascular Research, University of Edinburgh, Edinburgh, UK.
- Clinical Research Imaging Centre, University of Edinburgh, Edinburgh, UK.
- Department of Cardiology, Royal Infirmary of Edinburgh, Edinburgh, UK.
- Department of Vascular Surgery, Royal Infirmary of Edinburgh, Edinburgh, UK.
- Department of Radiology, Royal Infirmary of Edinburgh, Edinburgh, UK.
- Department of Cardiac Surgery, Royal Infirmary of Edinburgh, Edinburgh, UK.

Published: 30 January 2013

doi:10.1186/1532-429X-15-S1-O114

Cite this article as: Semple *et al.*: Quantitative myocardial inflammation assessed using a novel USPIO-Magnetic Resonance Imaging acquisition and analysis protocol. *Journal of Cardiovascular Magnetic Resonance* 2013 15(Suppl 1):O114.

Submit your next manuscript to BioMed Central and take full advantage of:

- Convenient online submission
- Thorough peer review
- No space constraints or color figure charges
- Immediate publication on acceptance
- Inclusion in PubMed, CAS, Scopus and Google Scholar
- Research which is freely available for redistribution

Submit your manuscript at
www.biomedcentral.com/submit

